


香港聖公會 預防青少年吸食危害精神毒品研討會 香港常見的**危害精神毒品**及對 身心構成的**傷害**

謝萬里醫生

醫院管理局中毒諮詢中心 顧問醫生



ML Tse

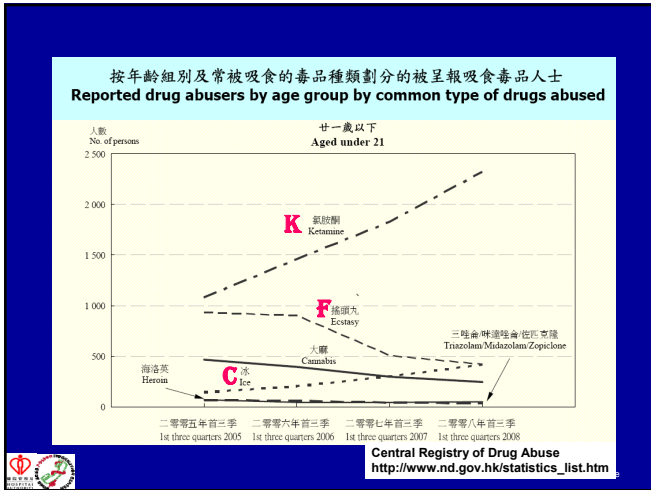
危害精神毒品



NARCOTICS ANALGESICS
 麻醉鎮痛劑
HALLUCINOGENS
 迷幻劑
DEPRESSANTS
 鎮抑劑
STIMULANTS
 興奮劑
TRANQUILIZERS
 鎮靜劑
OTHERS
 其他



ML Tse





興奮劑
 冰凍嘢 (甲基安非他命) Coke (可卡因)
其他
 E仔, 糖 (MDMA) 大麻, 草, 牛牛
鎮靜劑
 K (氯胺酮) 止咳水 白瓜子 (佐匹克隆 / 三唑倫)
 五仔, 黃飛鴻




ML Tse

Ketamine- K 仔




K (氯胺酮)
 海洛英 Heroin 冰 Ice 大麻 Cannabis 三唑倫 Trazolam 咪唑倫 Midazolam 佐匹克隆 Zopiclone



ML Tse

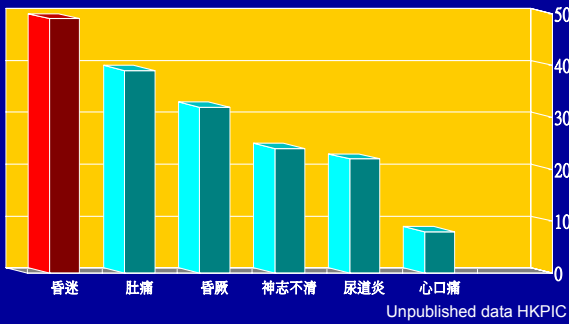
濫用K仔病人最普遍往急症室求醫原因

- A 昏迷
- B 肚痛
- C 尿道炎徵狀
- E 頭部創傷



ML Tse

242 個急症個案回顧

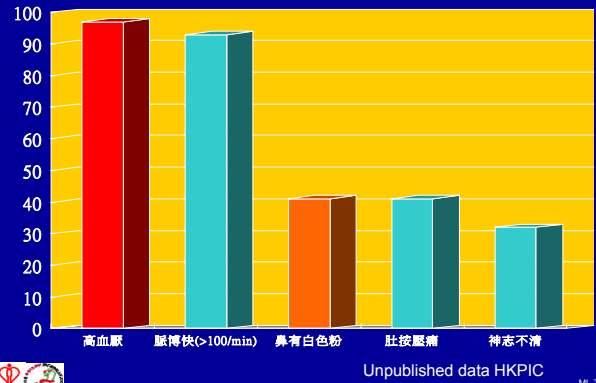


Unpublished data HKPIC



ML Tse

242 個急症個案回顧



Unpublished data HKPIC



ML Tse

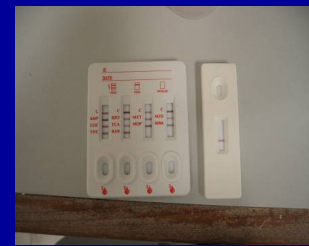隱藏K仔濫用者急症求診原因

- 肚痛
- 尿道炎
- 頭部受傷
- 鼻炎, 流鼻血等
- 交通意外



ML Tse

爆晒 – 神志不清




光環



ML Tse

- 胃痛, 上腹痛, 肚痛
- 肝炎



ML Tse

膽管抽筋

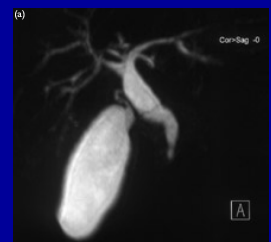
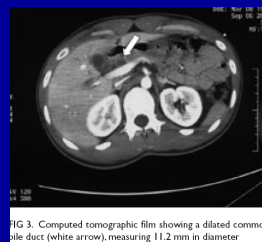
FIG 3. Computed tomographic film showing a dilated common bile duct (white arrow), measuring 11.2 mm in diameter


MEDICAL PRACTICE Dilated common bile ducts mimicking choledochal cysts in ketamine abuser: Wong SW et al. HKMJ 2009



ML Tse

K仔尿道炎—消失的膀胱症候群

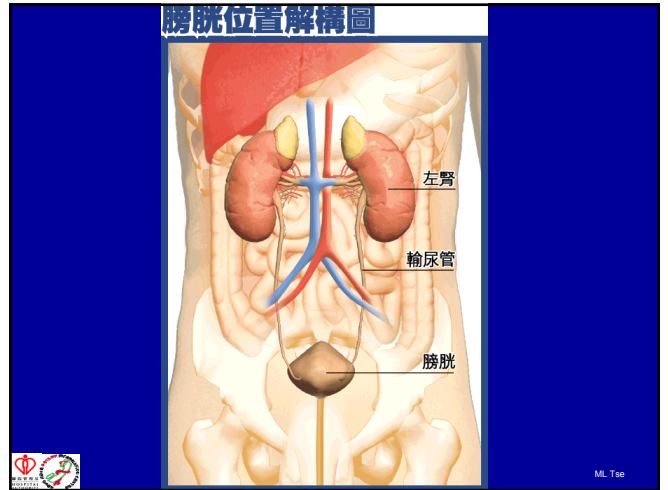
Ketamine damaged my bladder - now every bus trip becomes very long.



**No drugs No self-destruction
Not Now Not Ever**

Narcotics Division, Security Bureau Action Committee Against Narcotics www.na.gov.hk

ML Tse



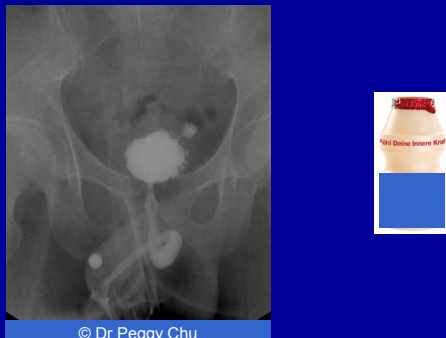
正常膀胱 500cc



© Dr Peggy Chu TMH

ML Tse

縮小了的膀胱 50cc

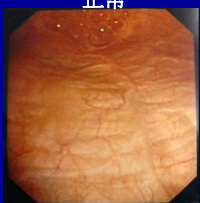


© Dr Peggy Chu

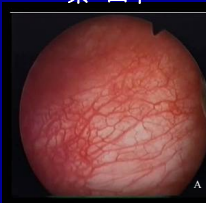
ML Tse

膀胱鏡

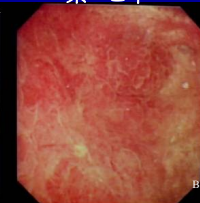
正常



索K四年



索K七年



© Dr Peggy Chu TMH

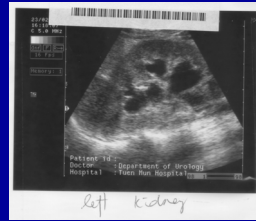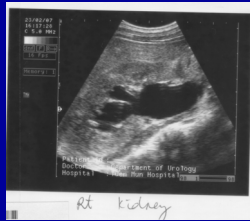ML Tse

徵狀

- 下腹痛
- 排尿痛
- 尿頻
- 血尿
- 小便困難
- 失禁

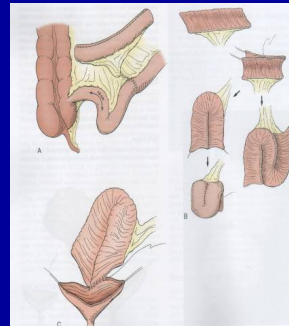
ML Tse

腎積水, 腎衰竭



© Dr Peggy Chu TMH

迴腸道膀胱擴大手術



ML Tse

K仔對鼻的損害



ML Tse

- 鼻塞
- 失去嗅覺
- 流鼻血
- 鼻炎



ML Tse

興奮劑



ML Tse

那一種危害精神毒品引起磨牙?

- A K仔
- B 大麻
- C 咳水
- D 糖 (E仔)



ML Tse

這是甚麼?



- A 追龍壺
- B 索K樽
- C 溜冰壺
- D 大麻瓶



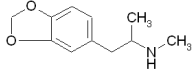
安非他命



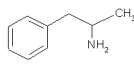
Fing 頭, E 仔, 精



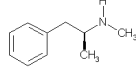
冰 凍 嘢
(甲基安非他命)



MDMA
亞甲二氧基甲基安非他命



Amphetamine
安非他命



Methamphetamine
甲基安非他命

© Lutheran Evergreen Centre



吸食冰的過程

“僕”冰 / 滑雪

跳掣 - 精神錯亂

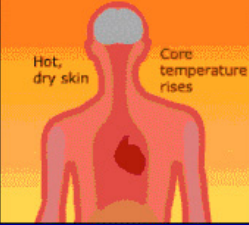- 妄想性, 迫害性幻覺
- 傷人, 自毀傾向



中暑

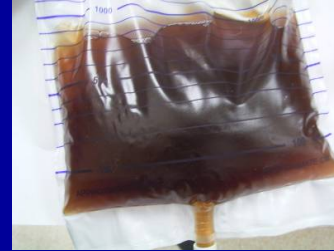EFFECTS OF HEAT ON THE BODY

Condition: Heat stroke
Sweating stops. Fainting. Danger of organ damage and death.



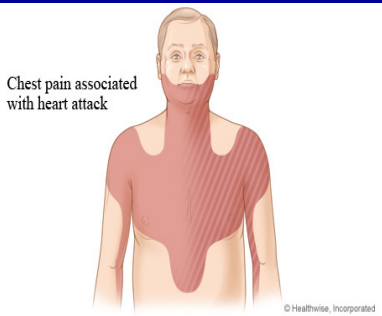
ML Tse

橫紋肌溶解



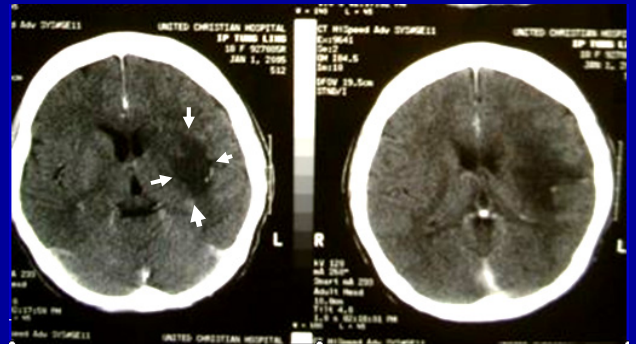
ML Tse

急性心臟病



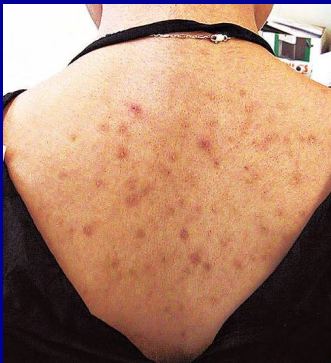ML Tse

中風-急性腦損傷



ML Tse

冰瘡



ML Tse


冰虫幻覺



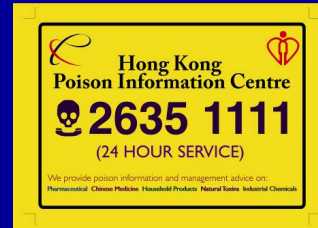ML Tse

長期腦損害

- 冇記性
- 反應慢
- 手眼協調差
- 手震
- 脾氣失控
- 幻覺: 逼害性
- 抽象思維受損
- 失智 (痴呆)



ML Tse



hkpic@ha.org.hk